

Subacromial impingement: is there correlation between symptoms, arthroscopic findings and outcomes?

Martyn Snow, Daniel Cheong & Lennard Funk

Upper Limb Unit, Wrightington Hospital, Hall Lane, Appley Bridge, Wigan, UK

ABSTRACT

Received

Submitted 22 June 2009;
accepted 29 June 2009

Keywords

Subacromial impingement, pain, arthroscopic decompression, satisfaction

Conflicts of interest

None declared

Correspondence

Lennard Funk, Upper Limb Unit, Wrightington Hospital, Hall Lane, Appley Bridge, Wigan, WN6 9EP, UK.

Tel: +44 (0)161 2270027.

Fax: +44 (0)161 2270028.

E-mail: lenfunk@shoulderdoc.co.uk

DOI:10.1111/j.1758-5740.2009.00022.x

Background To determine whether a correlation exists between the clinical symptoms and signs of impingement, and the severity of the lesions seen at bursoscopy.

Methods Fifty-five patients who underwent arthroscopic subacromial decompression were analyzed. Pre-operatively patients completed an assessment form consisting of visual analogue pain score, and shoulder satisfaction. The degree of clinical impingement was also recorded. At arthroscopy impingement was classified according to the Copeland-Levy classification. Post-operatively the shoulder assessment was repeated. Statistical analysis was carried to determine if the degree of impingement at arthroscopy correlated with pre-operative pain, satisfaction and clinical signs of impingement.

Results Pre-operative pain level, shoulder satisfaction and degree of clinical impingement did not correlate significantly with severity of the lesions of the acromion and cuff. (average correlation coefficient r^2 0.018.) There was no correlation between the improvement in the shoulders post-operatively and the severity of lesions (r^2 0.008).

Conclusion There was no correlation between pain, clinical signs or outcomes of subacromial decompression and the severity of impingement lesions seen at arthroscopy.

INTRODUCTION

Impingement syndrome results from repetitive trauma and compression of the rotator cuff tendons and bursa between the tubercle of the humeral head and anterior edge of the acromion [1]. Chronic impingement can lead to rotator cuff tendonitis, subacromial bursitis and rupture of the rotator cuff tendons [2].

It has been demonstrated that the incidence of rotator cuff tears is increased with type II and III acromions [3,4]. Type III acromions also cause significantly larger rotator cuff tears through impingement [5]. Thus there appears to be a direct relationship between acromial morphology and impingement lesions of the rotator cuff.

In theory, the amount of pain the patient experiences should be proportional to the severity of impingement and the corresponding lesions of the rotator cuff and acromion. At present there is no evidence in the literature which demonstrates a correlation between pain and arthroscopic findings. The aim of our study was to determine whether a correlation exists between the clinical symptoms and signs of impingement syndrome, and the severity of impingement lesions seen at arthroscopy. Also we aimed to determine if patient satisfaction was directly proportional to the severity of impingement.

METHODS

A total of 55 patients diagnosed with impingement syndrome who subsequently underwent subacromial decompression were analyzed prospectively. The sample size was recommended by

a medical statistician, based on a small preliminary pilot study. All patients were diagnosed with impingement by a single physician. Diagnostic criteria included patients with a good history of impingement, and two or more positive clinical tests (from Hawkins test, Neer's sign and Copeland impingement test). The definitive diagnosis was then confirmed at arthroscopy as determined by Iannotti et al. [6]. All patients were operated on by a single surgeon. Patients diagnosed with concomitant conditions at arthroscopy were excluded from the study. At arthroscopy the anterolateral edge of the acromion was resected and bevelled posteriorly. The coracoacromial ligament was released from the acromion and resected.

Prior to surgery all patients completed a shoulder assessment form. This was completed independently of the clinician, in the waiting room. It consisted of a visual analogue pain score (0–13) and a satisfaction score (both taken from the Constant score). The degree of impingement on clinical examination was also graded by the physician as either mild, moderate or severe.

At arthroscopy the lesions of the acromion and rotator cuff were noted for each patient. The lesions were described according to the Copeland-Levy classification [7] (Table 1).

At 6 months post surgery the visual analogue and satisfaction scores were repeated. Linear regression coefficients were calculated for the grade of acromion, cuff and combined lesions for each of the three outcome measures. A combined lesion was an equal score on both sides, such as A1B1. Equal lesions were much more

Table 1 Copeland-Levy classification of impingement lesions at arthroscopy [7]

Impingement lesion acromion	Impingement lesion cuff
A0 –Normal	B0 –Normal
A1 –Minor scuffing	B1 –Minor scuffing
A2 –Marked scuffing	B2 –Major scuffing, partial thickness tear
A3 –Bare bone areas	B3 –Full thickness tear
	B4 –Massive cuff tear

common than differential lesions (e.g. A1B3) and therefore only these were analyzed.

RESULTS

Fifty-five patients were analyzed with a mean age at surgery of 56.6 years. There were 25 males and 30 females. On arthroscopic examination, the most common lesion of the rotator cuff was B2 (58% of patients) and the most common lesion of the acromion was A2 (71% of patients).

The distribution of pre-operative pain scores according to lesion are shown in Table 2. There was no statistically significant correlation between the severity of pain and the grade of acromial, rotator cuff or combined lesions (Table 3). The pre- and post-operative satisfaction scores according to lesion are shown in Table 2. There was also no statistical correlation between pre-operative or post-operative satisfaction and degree of impingement (Table 3).

Six patients (11%) deemed to have mildly positive impingement tests pre-operatively had a mean combined lesion score of 3.7.

Table 2 Results of data analysis

	Pre-operative pain level	Pre-operative satisfaction	Post-operative satisfaction increase
Cuff lesion			
0	6.7	2.7	4
1	5	0.5	5.5
2	5.4	2.1	5.1
3	4.8	1.8	6.1
4	4	3.1	4.4
Acromion lesion			
0	6.6	2.4	5.2
1	3.7	1.8	6.2
2	4.8	2.4	5.3
3	5.8	1.8	3.4
Cuff + acromion lesion			
0	6.7	2.7	4
1	N/A	N/A	N/A
2	6.6	1.8	6.6
3	1.5	3.5	5.5
4	5	2.2	4.8
5	4.5	1.3	7.5
6	3.6	3.4	2.8
7	6	1.7	4.3

Table 3 A summary of the correlation coefficients for pain and satisfaction (pre and post-operatively) vs the grade of combined impingement scores

	Acromion lesion	Cuff lesion	Combined lesion
Pre-operative pain level	0.009	0.03	0.03
Pre-operative satisfaction	0.004	0.001	0.0002
Post-operative satisfaction	0.02	0.003	0.001

Forty patients (72%) with moderately positive impingement tests had a mean combined lesion score of 4.1 and eight patients (17%) with markedly positive impingement tests had a mean combined lesion score of 4.4. There was no statistically significant correlation between the impingement tests and the combined lesions. Regression analysis plots for pain, impingement tests and satisfaction are shown in Figures 1 to 3.

Six patients (11%) had no improvement after surgery and 89% of patients were satisfied. The full data set for all patients is shown in Appendix S1.

DISCUSSION

In 1972, Neer [8] described acromion alterations attributable to mechanical impingement. He described a large anterior acromial spur and excrescences of the anterior third, which he believed to be characteristic of chronic impingement with traction on the coracoacromial ligament. It has since been assumed that the severity of these architectural changes is proportional to the symptoms associated with impingement. We could find no such correlation in our study

A previous study by Soyer et al. [9] investigated outcomes following arthroscopic subacromial decompression. They found that the improvement in pain post-operatively was not related to the amount of acromion resected at operation, and thus the severity of impingement. It confirms that the origins of pain in impingement are multifactorial and not solely related to mechanical factors. The exact source of the pain appears to be unclear. It has been shown that resection of the acromion and/or the coracoacromial ligament results in clinical improvement, although no direct relationship has been shown to exist. This has lead investigators to suggest that relief from impingement syndrome could result from the resection of the thickened bursal tissues. Soifer et al. [10] showed a rich neural innervation of the subacromial space, especially of the subacromial bursa. The nociceptive information relayed by free nerve ends may be responsible for the pain associated with the impingement syndrome and rotator cuff pathology. This may explain the relief of pain after arthroscopic debridement. We remain sceptical of this theory as bursal resection is not a routine practice for us when undertaking an arthroscopic decompression.

Clinical diagnosis in our study was based on two positive clinical tests. The Neer, Hawkins and Copeland’s tests have all been shown

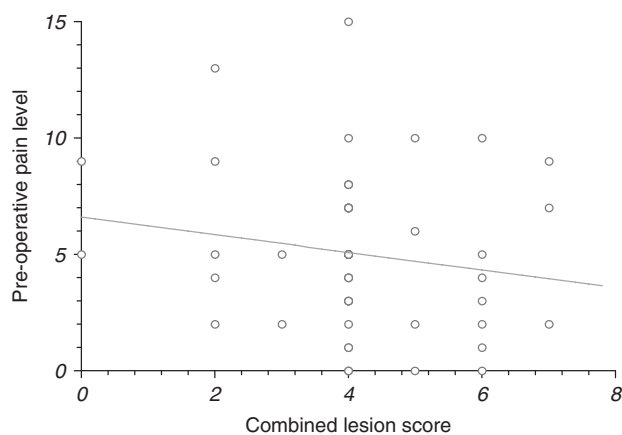


Fig. 1 Linear regression showing combined lesion score against pre-operative pain level.

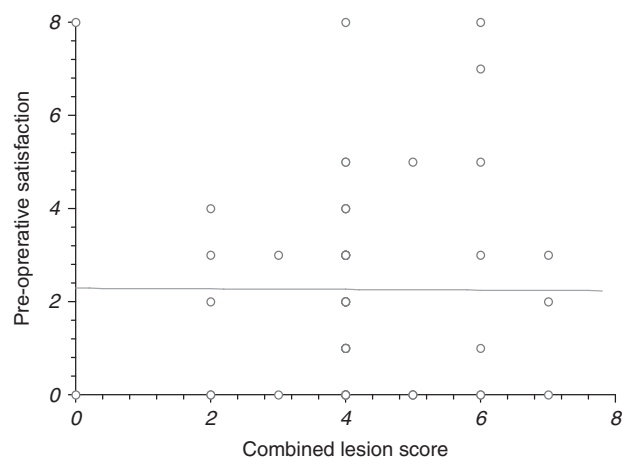


Fig. 2 Linear regression showing combined lesion score against pre-operative satisfaction.

to be highly sensitive for impingement. These tests are based on the morphological changes associated with impingement, and similar to pre-operative pain, there is no correlation with severity. Whilst positive tests can predict a good outcome post surgery [11], they cannot indicate the grade of impingement. Thus the need for decompression should be based on the combination of pain and positive tests and not the subjective severity of impingement found on examination.

The correlation between the severity of impingement lesions and satisfaction post-operatively was not statistically significant in our study. Debate still exists regarding the relationship between outcome and the severity of impingement. There is evidence in the literature to support a number of theories. Hoe-Hanson et al. [12] and Chui et al. [13] confer with our results and show no direct relationship. Esch et al. [14] reported a higher satisfaction post-op in patients with complete or partial cuff tears, as did Adholfson & Lisholm [15]. By contrast Gartman [16] and Patel et al. [17] reported that patients with impingement but no rotator cuff tears had better results.

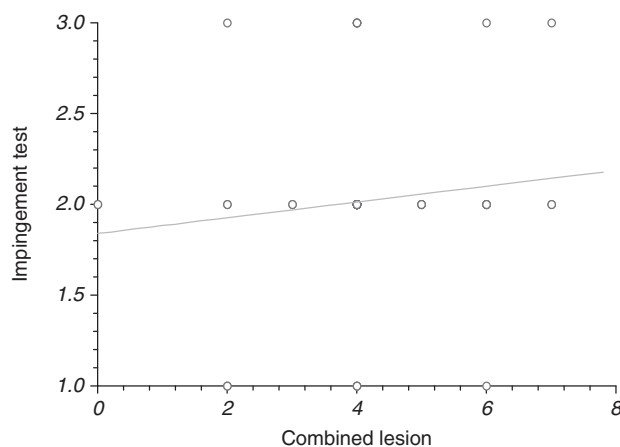


Fig. 3 Linear regression showing combined lesion score against impingement test (1 = mild, 2 = moderate, 3 = marked).

The reported results of acromioplasty vary widely. However meta-analysis has shown the overall success rate to be approximately 85% [18]. In our study 89% of patients were satisfied with the outcome of surgery. From our study the need for decompression should not be made according to the severity of impingement lesion. If a diagnosis of impingement has been made both clinically and arthroscopically then a decompression should be carried out. Even minor impingement can cause significant pain which improves following decompression.

In conclusion, in our study there was no significant correlation between pain or pre-operative clinical findings and the severity of impingement lesions seen at arthroscopy. Similarly there was no correlation between the severity of lesions and post-operative satisfaction. The need for decompression should be based on a pain with positive clinical findings and not on the severity of impingement lesions at arthroscopy.

References

1. **Simm E, Hill J.** Rotator cuff injuries: an update. *J Orthop Sports Phys Ther* 1989; 10:394–8.
2. **Neer CS.** Impingement lesions. *Clin Orthop* 1983; 173:70.
3. **Bigliani LU, Morrison DS, April EW.** Morphology of the acromion and its relationship to rotator cuff tears. *Orthop Trans* 1986; 10:459–60.
4. **Iannotti JP. ed.** *Rotator cuff disorders: evaluation and treatment, American Academy of Orthopaedic Surgeons Monograph Series.* Park Ridge: Highwire Press. 1991: 5.
5. **Mako Hirano MD, Junji Ide MD, Katsumasa Takagi MD.** Acromial shapes and extension of rotator cuff tears: Magnetic resonance imaging evaluation. *J Shoulder and Elbow Surg* 2002; 11:576–8.
6. **Iannotti JP, Zlatkin MB, Esterhai JL, et al.** Magnetic resonance imaging of the shoulder. Sensitivity, specificity and predictive value. *J Bone Joint Surg* 1991; 73:17–29.
7. **Levy O, Sforza G, Dodenhoff RM, Copeland SA.** Arthroscopic evaluation of the impingement lesion: pathoanatomy & classification. *J Bone Joint Surg (Br)* 2000; (Suppl III):233.
8. **Neer CS.** Anterior acromioplasty for chronic impingement syndrome in the shoulder: a preliminary report 1972. *J Bone Joint Surg* 1972; 54:41–50.

9. **Soyer J, Vaz S, Pries P, Clarac JP.** The relationship between clinical outcomes and the amount of arthroscopic acromial resection. *Arthroscopy* 2003; 19(1):34–9. 12 2 2 7 3 9
10. **Soifer TB, Levy HJ, Soifer FM,** et al. Neurohistology of the subacromial space. *Arthroscopy* 1996; 12:182–6. 13 3 2 2 0 10
11. **Mair SD, Viola RW, Gill TJ, Briggs KK, Hawkins RJ.** Can the impingement test predict outcome after arthroscopic subacromial decompression? *J Shoulder Elbow Surg* 2004; 13(2): 150–3. 14 1 1 2 2 10
12. **Hoe-Hanson CE, Palm L, Norin R.** The influence of cuff pathology on shoulder function after arthroscopic subacromial decompression: a 3- and 6-year follow-up study. *J Shoulder Elbow Surg* 1999; 8: 585–9. 15 2 2 3 8 7
13. **Chui CH, Lee C, Seow KH.** The results of open acromioplasty in impingement syndrome—a retrospective study. *Singapore Med J* 1997; 38:22–4. 16 2 2 7 2 10
14. **Esch JC, Ozerkis IR, Helgagger JA.** Arthroscopic subacromial decompression: results according to degree of rotator cuff tear. *Arthroscopy* 1988; 4:241–9. 17 2 2 5 3 8
15. **Adolfson L, Lysholm J.** Results of arthroscopic subacromial decompression according to cuff lesion. *Int Orthop* 1993; 17: 228–31. 18 3 3 10 3 5
16. **Gartman G.** Arthroscopic acromioplasty for lesions of the rotator cuff. *J Bone Joint Surg* 1990; 72:169–80. 19 2 2 4 0 6
17. **Patel VR, Singh D, Calvert PT, Bayley JIL.** Arthroscopic subacromial decompression: results and factors affecting outcome. *J Shoulder Elbow Surg* 1999; 8:231–7. 20 2 2 5 0 10
18. **Canale T. ed.** *Operative orthopaedics*. Vol. 3. Tenth edition. New York: Mosby. 2003; 2340–2344. 21 4 2 5 5 7
- 22 4 3 9 3 3
- 23 3 1 4 4 8
- 24 4 3 2 0 10
- 25 4 2 2 8 5
- 26 3 2 0 0 10
- 27 2 2 3 0 8
- 28 2 0 13 4 10
- 29 2 2 0 1 2
- 30 2 2 7 3 8
- 31 3 1 1 2 8
- 32 2 2 8 4 6
- 33 2 2 5 1 5
- 34 1 2 5 3 6
- 35 3 3 1 1 3
- 36 4 3 7 2 5
- 37 2 2 1 1 8
- 38 4 2 0 0 10
- 39 2 2 7 1 8
- 40 2 2 4 0 9
- 41 2 2 5 3 5
- 42 2 2 10 3 9
- 43 2 0 5 0 8
- 44 2 2 15 0 6
- 45 2 2 8 5 10
- 46 0 0 5 0 3
- 47 1 1 9 3 8
- 48 2 2 5 3 7
- 49 2 1 2 0 8
- 50 0 0 9 8 7
- 51 3 2 6 0 10
- 52 2 2 0 1 7
- 53 2 2 5 1 7
- 54 2 2 5 2 8

Appendix S1: Full data set

Patient number	Lesion cuff	Lesion acromion	Level of pain	Pre-satisfaction	Post-satisfaction						
1	2	2	3	1	8	44	2	2	15	0	6
2	2	2	7	5	7	45	2	2	8	5	10
3	4	2	3	7	7	46	0	0	5	0	3
4	3	2	10	5	10	47	1	1	9	3	8
5	1	1	4	0	6	48	2	2	5	3	7
6	2	2	5	4	3	49	2	1	2	0	8
7	2	2	8	2	6	50	0	0	9	8	7
8	2	2	5	3	7	51	3	2	6	0	10
9	4	2	4	0	7	52	2	2	0	1	7
10	2	2	2	2	2	53	2	2	5	1	7
11	2	2	3	0	10	54	2	2	5	2	8